Journal of Clinical and Translational Pathology **2024**
DOI: 10.14218/JCTP.2023.00064

Case Series

Disseminated Carcinomatosis of Bone Marrow with or without an Unknown Primary Site: A Case Series

Kenji Miki[1], Masayoshi Yamanishi[1], Satoko Mibayashi[2] and Shinsaku Imashuku[3*]

[1]*Department of Internal Medicine, Uji-Tokushukai Medical Center, Uji, Kyoto, Japan;* [2]*Department of Diagnostic Pathology, Uji-Tokushukai Medical Center, Uji, Kyoto, Japan;* [3]*Department of Laboratory Medicine, Uji-Tokushukai Medical Center, Uji, Kyoto, Japan*

Received: December 9, 2023 | **Revised:** January 24, 2024 | **Accepted:** April 10, 2024 | **Published online:** May 14, 2024

Abstract

Background and objectives: Disseminated carcinomatosis of bone marrow (DCBM) occurs mostly in stomach cancer patients; however, characterizing tumor cells morphologically and phenotypically in the bone marrow is not an easy task. In addition, among patients with DCBM, an unknown primary site (CUPS) is rarely noted despite standard clinical evaluation, imaging studies, and endoscopic findings. This study aimed to clarify the diagnosis/outcome of DCBM in elderly patients we have treated. ***Methods:*** Here, we report eight DCBM cases. Once tumor clumps were noted in the bone marrow, we performed serum tumor markers, immunostaining of tumor cells in the bone marrow clot, or biopsy preparations. In addition, imaging studies (CT/MRI/FDG PET-CT) were performed. ***Results:*** Of eight cases, two were diagnosed with DCBM/CUPS, whose clinical course is described in detail. The outcomes of DCBM and DCBM/CUPS, particularly in elderly patients were dismal and we could not perform comprehensive genomic profiling in these cases. ***Conclusions:*** To improve the DCBM patients' prognosis through the use of conventional morphological/phenotypical characteristics is limited. Recently, the application of comprehensive genomic profiling has been recommended. However, we encountered difficulty in applying comprehensive genomic profiling for the treatment of elderly patients with DCBM/CUPS.

Citation of this article: Miki K, Yamanishi M, Mibayashi S, Imashuku S. Disseminated Carcinomatosis of Bone Marrow with or without an Unknown Primary Site: A Case Series. J Clin Transl Pathol 2024. doi: 10.14218/JCTP.2023.00064.

Introduction

Bone marrow is one of the various organ sites of metastasis of solid tumors.[1] The detection of metastatic tumor cells in the bone marrow can be achieved by a combination of bone marrow aspiration smear (BMAS), clot preparation of bone marrow aspiration, and bone marrow biopsy preparation (BMBP). Particularly, clot preparation of bone marrow aspiration and BMBP are more useful than BMAS for the detection and immunostaining of tumor cells. Disseminated carcinomatosis of bone marrow (DCBM) occurs mostly in stomach cancer patients and is often associated with disseminated coagulation.[2] On the other hand, cancer of unknown primary site (CUPS) is defined as a histologically confirmed, metastatic malignancy with an unidentifiable primary tumor site based on standard evaluation and imaging studies. CUPS is clinically characterized as an aggressive disease with early dissemination and comprises 2–5% of all diagnosed cancers worldwide.[3] In CUPS, most tumors are either adenocarcinoma or undifferentiated carcinoma,[4] and metastatic adenocarcinoma is the most common histopathology (80%).[5] Among DCBM/CUPS cases, adenocarcinoma, neuroendocrine carcinoma, and melanoma have been described.[6–8] Although the primary site can generally be suspected from the morphology and immunohistochemistry of metastatic cells in the bone marrow and can be identified by endoscopic and imaging (CT/ MRI/ FDG PET-CT) studies, there are still cases of CUPS, such as the case of melanoma, in which bone marrow biopsy detected HMB-45- and S100-positive atypical large cells with brown pigmentation; however, skin lesions were not observed on the body surface.[8] Over the past 6 years since 2017, we experienced 8 cases of DCBM, two of which were DCBM/CUPS cases. Here, we focused on these two cases in which the tumor clumps of metastatic cells in the bone marrow were poorly differentiated and the primary site could not be identified.

Methods

We studied eight DCBM cases. Once tumor clumps were noted in the bone marrow, we performed serum tumor markers, immunostaining of tumor cells in the bone marrow clot, or biopsy preparations. In addition, imaging studies (CT/MRI/ FDG PET-CT) were performed to locate the primary site.

This case study was performed in accordance with the guidelines of the Declaration of Helsinki and approved by the Ethics Committee at the Uji-Tokushukai Medical Center after obtaining written informed consent from each patient before the study.

Keywords: Cancer of unknown primary site; Disseminated carcinomatosis of bone marrow; Tumor clumps; Tumor marker; FDG PET-CT; Comprehensive genomic profiling.

*__Correspondence to:__ Shinsaku Imashuku, Department of Laboratory Medicine, Uji-Tokushukai Medical Center, Uji, Kyoto 611-0041, Japan. ORCID: https://orcid.org/0000-0001-9795-0819. Tel: +81-774-20-1111, Fax: +81-774-20-2336, E-mail: shinim95@mbox.kyoto-inet.or.jp

Copyright: © 2024 The Author(s). This article has been published under the terms of Creative Commons Attribution-Noncommercial 4.0 International License (CC BY-NC 4.0), which permits noncommercial unrestricted use, distribution, and reproduction in any medium, provided that the following statement is provided. "This article has been published in *Journal of Clinical and Translational Pathology* at https://doi.org/10.14218/JCTP.2023.00064 and can also be viewed on the Journal's website at https://www.xiahepublishing.com/journal/jctp".

Results

Summary of 8 DCBM cases

A total of 8 cases are summarized in Table 1. All cases were males, with a median age of 71 years (ranging from 37 to 82. Among the 8 cases, two had poorly differentiated adenocarcinoma or undifferentiated carcinoma (Cases 1 and 2; Fig. 1a and b), two had gastric carcinomas (Cases 3 and 4; Fig. 2a and b), two had endothelial hemangioendothelioma (EHE) (Cases 5 and 6, no figures), one had urothelial cell carcinoma (Case 7; Fig. 2c) and one had lung small cell carcinoma (SCC) (Case 8; Fig. 2d). In these cases, only precursor of gastrin-releasing peptide (Pro-GRPS) among the serum tumor markers was used to diagnose lung SCC. In contrast, carcinoembryonic antigen (CEA), neuron-specific enolase (NSE), and Pro-GRPS, which were mildly or moderately elevated in Case 2, could not be helpful for diagnosis. Immunohistochemical staining did not assist in identifying the primary site of cancer in CUPS cases. In 6 of the 8 metastatic tumor cells were detectable in patients with BMAS/BMBP, but in EHE cases (Cases 5 and 6), we needed BMBP for a correct diagnosis. Among the 8 cases, 6 fatal cases had a median survival time of 2 months (ranging from <0.5 to 8 months) from DCBM detection to death or the time of this writing while CUPS cases were still alive at 2+ and 3+ months, respectively.

Two cases of DCBM/CUPS

Case 1: A 75-year-old male was referred with high serum C-reactive protein (CRP) and anemia. On admission, he was noted to have pleural fluid/ascites and bilateral lower leg edema but without hemorrhagic diathesis. He had no history of malignancies and never underwent gastrectomy. Laboratory data showed a white blood cell count of 13,000/μL (no abnormal cells), Hb of 9.8 g/dL, and a platelet count of 311 K/μL, and no schistocytes were noted on the blood smear. Serum CRP was 16.2 mg/dL (reference: <0.14 mg/dL), lactate dehydrogenase was 340 U/L (reference range: 124–222 U/L), alkaline phosphatase was 187 U/L (reference range: 80–260 U/L), and ferritin was 1,284 ng/mL (reference range: 21–282 ng/mL). He was noted to have low serum folate (0.9 ng/mL; reference range 3.6–12.9 ng/mL) and low serum vitamin B12 (166 pg/mL; reference range 233–914 pg/mL). Hepatic and renal function were normal. Immunologically, the patient was ANA-negative but PR3-ANCA-positive. The levels of the tumor markers prostate-specific antigen (PSA) (0.15 ng/mL: reference range <4.0), CA19-9 (<2.00 U/mL: reference range; <2.00), and CEA (4.03 ng/mL: reference range <5.0) were all within normal limits. After admission, methicillin-sensitive Staphylococcus aureus septicemia due to catheter-related bloodstream infection was successfully managed with ceftriaxone/vancomycin. Because of high serum CRP levels, various studies have been carried out. On CT imaging, no signs of suspected tumor(s) were detected other than a moderately enlarged prostate. The upper and lower gastrointestinal endoscopies did not show any abnormal findings. FDG PET-CT revealed only diffuse FDG-avid signals in the entire bones/bone marrow of the flat and long bones (Fig. 3a). The poorly differentiated adenocarcinoma-like tumor cell clumps in BMAS are shown in Figure 1a. Bone marrow biopsy also revealed the proliferation of abnormal cells with nuclei with distinct nucleoli and eosinophilic cytoplasm among the fibrous stroma (Fig. $3b_1$). Immunostaining of the abnormal cells showed positivity for only AE1/3, CK20, and vimentin (Fig. $3b_{2-4}$). Staining results for CK7, S100, CDX2, GATA3, p40, and TTF-1 were negative, while PAX5 and PSA were equivocal (data not shown). These data

Table 1. Eight cases of DCBM

Cases	Age (yrs.)	Gender	Detection of tumor cells in BM	Diagnosis	Serum tumor markers	IHS positivity in BMBP	Survival from DCBM detection (months)
Case 1	75	M	BMAS/BMBP	CUPS	None	AE1/3, CK20, vimentin	3+
Case 2	82	M	BMAS/BMBP	CUPS	CEA, NSE, Pro-GRPS	AE1/3	2+
Case 3	81	M	BMAS/BMBP	Gastric carcinoma	None	PAS, CAM5.2	<0.5
Case 4	42	M	BMAS/BMBP	Gastric carcinoma	None	AE1/3, CAM5.2	2.5
Case 5	37	M	BMBP	EHE	None	CD31, CD34, FVIII, CAMTA1	<2
Case 6	76	M	BMBP	EHE	None	CD31, CD34, FVIII, CAMTA1	8
Case 7	66	M	BMAS/BMBP	Urothelial carcinoma	None	AE1/3, CK7, CK20, GATA3	1.5
Case 8	66	M	BMAS/BMBP	Lung SCC	Pro-GRPS	CD56, AE1/3, Synaptophysin, Ki-67(~90%)	2

BM, bone marrow; BMAS, bone marrow aspiration smear; BMBP, bone marrow biopsy preparation; CEA, carcinoembryonic antigen; CUPS, cancer of unknown primary site; DCBM, disseminated carcinomatosis of bone marrow; EHE, endothelial hemangioendothelioma; IHS, immunohistochemical staining; NSE, neuron-specific enolase; PAS, periodic acid-schiff stain; Pro-GRPS, precursor of gastrin-releasing peptide; SCC, small cell carcinoma.

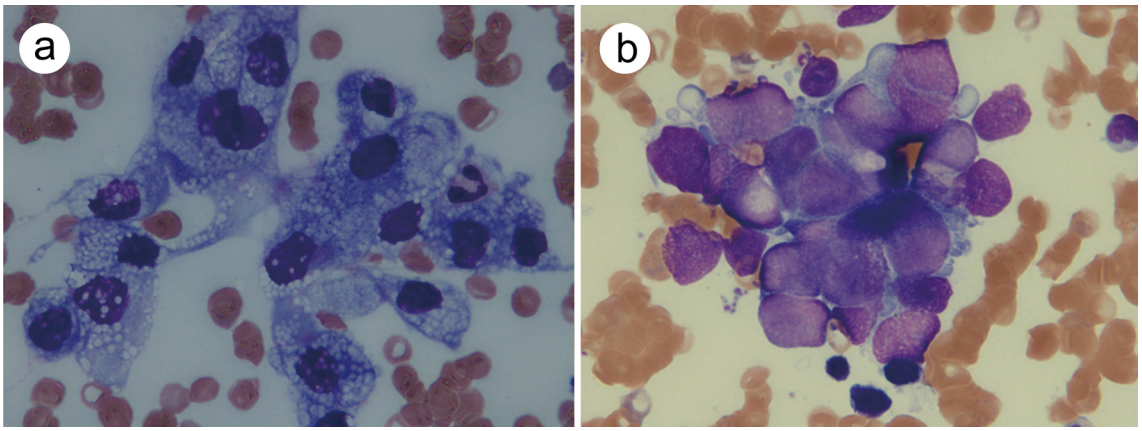

Fig. 1. Bone marrow smear revealed (a) Case 1, poorly differentiated adenocarcinoma; (b) Case 2, undifferentiated carcinoma (May Giemsa stain; original magnification, ×1,000).

suggested poorly differentiated adenocarcinoma (probably gastrointestinal/pancreaticobiliary carcinomas), excluding squamous cell carcinoma. urothelial/colon/lung carcinomas; however, the primary site remains unknown. Karyotypes of BM cells yielded 2 abnormal hypodiploid (mode 42) clones. One of the hypodiploid clones was 42, -X, -Y, -1, add (2) (q21), -4, add (11) (p11.2), -13, -14, -14, -18, +der(?) t (?; q21) × 2, +2mar. Based on these results, the patient was diagnosed with DCMB/CUPS. Because the patient was elderly, no chemotherapy was given. After receiving radiotherapy for painful bone sites, he was treated in the palliative medical facility. Consequently, comprehensive genomic profiling (CGP) was not performed.

Case 2: An 82-year-old male presented to the Urology Department for urinary infection, right gluteus maximus abscess, and prostate enlargement. The balloon was placed because of urinary retention due to suspected prostate hypertrophy when he was found to have DCBM (Fig. 1b). He was

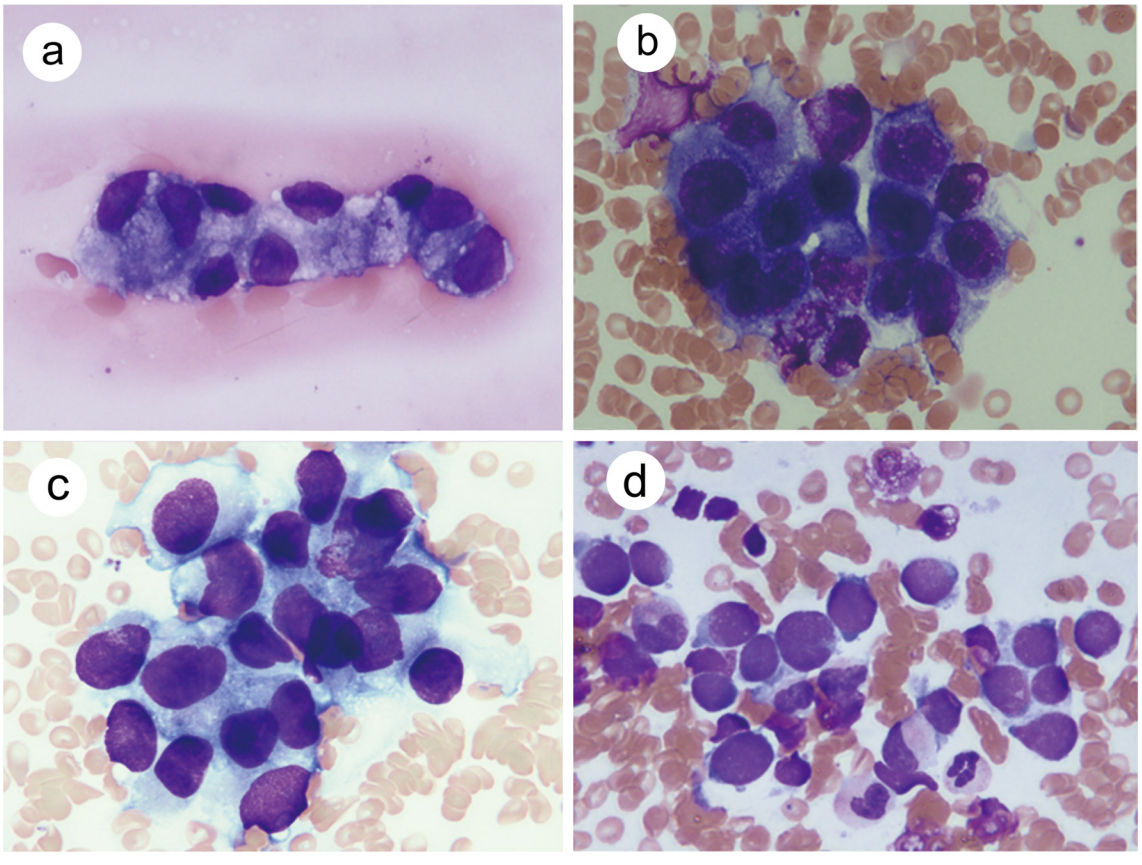

Fig. 2. Bone marrow smear was used to detect (a) Case 3, adenocarcinoma of gastric carcinoma; (b) Case 4, adenocarcinoma of gastric carcinoma; (c) Case 7, urothelial carcinoma; and (d) small cell carcinoma of the lung (May Giemsa stain; original magnification, ×1,000).

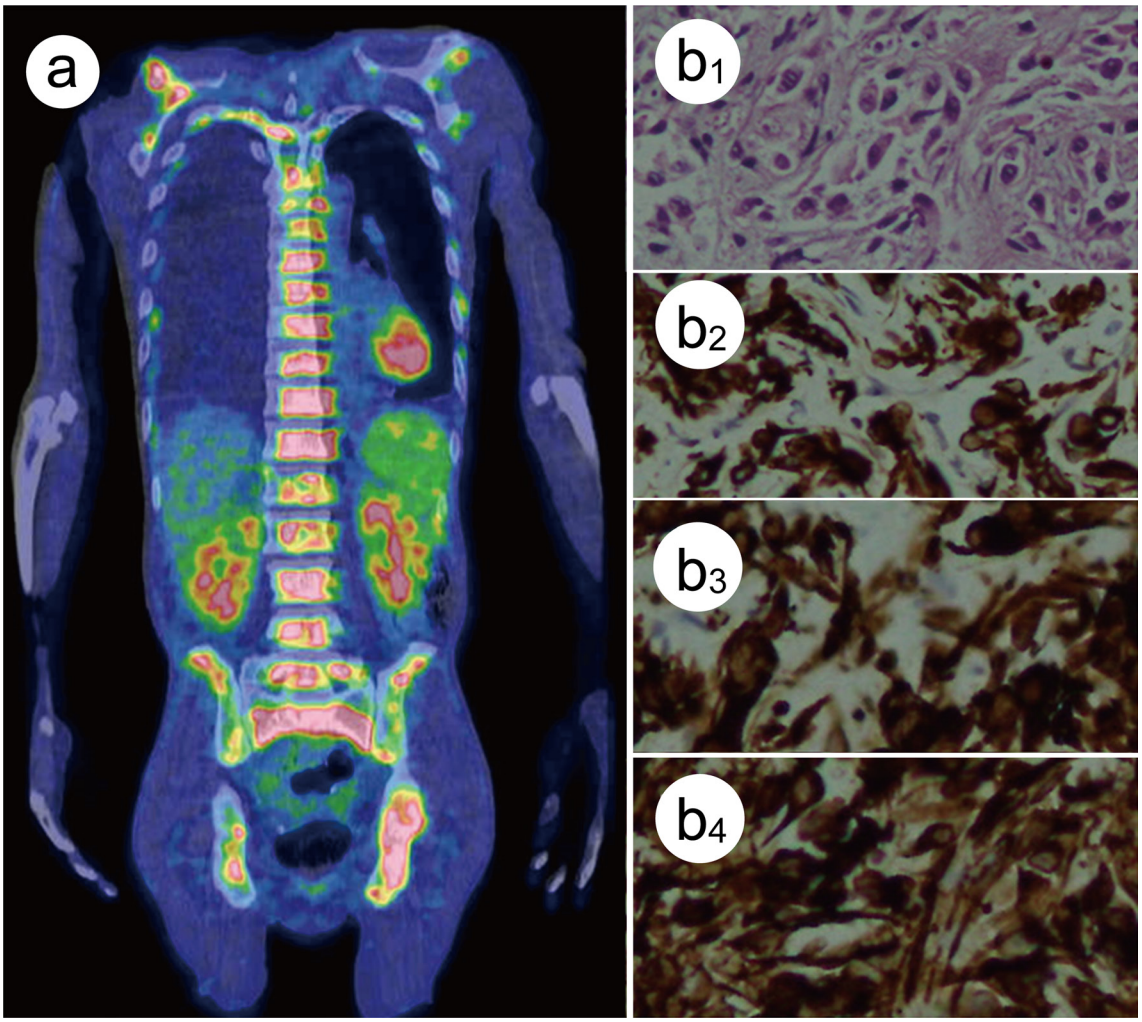

Fig. 3. Imaging and bone marrow histopathological studies in Patient 1. (a) FDG PET-CT image showing diffuse FDG-avid signals only in the bones/bone marrow. The lack of abnormal signals in the skin, lungs, gastrointestinal tract, pancreas, or prostate suggested that the primary site of cancer was unknown. The clumps of poorly differentiated adenoma cells in the bone marrow smear in this patient are shown in Figure 1a. The BMBP study shows (b_1) H&E staining and positive immunostaining results for (b_2) AE1/3, (b_3) CK20, and (b_4) vimentin (original magnification, ×200). Other negative staining results are not shown. BMBP, bone marrow biopsy preparation; FDG PET-CT, ^{18}F-fluorodeoxyglucose positron emission tomography-computed tomography.

anemic but neither icteric nor hemorrhagic. Laboratory data showed a white blood cell count of 6,900/μL, Hb of 6.4 g/dL, platelet count of 214 K/μL, serum CRP of 1.21 mg/dL, LDH of 233 U/L, and ALP of 969 U/L, and hepatic and renal function were normal. On CT imaging, disseminated bone metastasis was suspected to be associated with a spinal L1 compression fracture. In addition, a soft tissue shadow was noted at the pararectal fossa, suggesting peritoneal dissemination of cancer. However, a precise primary tumor site was not identified. His serum tumor markers were PSA 1.9 ng/mL (reference: <4.0 ng/mL), CEA 6.74 ng/mL (reference: <5 ng/mL), HCG <1.0 mIU/mL (reference: <19 mIU/mL), CA19-9 13.9 U/mL (reference: <2.00 U/mL), AFP 2.57 ng/mL(reference: <13.7 ng/mL), PIVKA-II 135 mAU/mL (reference: <39 mAU/mL), NSE 19.7 pg/mL (reference: <16.3 pg/mL), sIL-2R 826 U/mL (reference: <496 U/mL), SCC 0.8 ng/mL (reference: <1.5 ng/mL), Pro-GRPS 288 pg/mL (reference: <81 pg/mL), and calcitonin <0.5 pg/mL (reference: <5.15 pg/mL). The patient had normal hepatic and renal function. Immunohistochemical staining of BMBP showed that AE 1/3 was positive, while CK7, CK20, p40, TTF-1, synaptophysin, chromogranin A, and PSA were not positive. The karyotype of BM cells was 45, X -Y [5]/46, XY [15]. This abnormal chromosome was thought to be caused by myelodysplasia rather than by metastatic tumor cells. Like Case 1, this case was also elderly; thus, no chemotherapy was given, and the patient was transferred to the palliative medical facility.

Discussion

Metastatic tumor cells in the bone marrow can be first detected on BMAS. The morphology of the tumors varied, as shown in Figures 1 and 2; the majority formed tumor clumps, but SCC of the lung did not, mimicking lymphoma cells (Fig. 2d). Further characterization of tumor cells requires clot preparation or BMBP. In some malignancies like angiosarcoma or EHE,[9–11] BMAS is not helpful for diagnosis; thus, BMBP with specific immunostaining, such as CD31, CD34, FVIII, and CAMTA1, is required to make a diagnosis (data not shown). However, characterizing metastatic

tumor cells in addition to angiosarcoma/EHE by immunohistochemical staining is often difficult to determine the precise characteristics (see Table 1). In addition, identifying a tumor's primary site depends on the clinicians' hands with clinical data, imaging (CT/MRI/FDG PET-CT) studies, and endoscopic findings. The use of serum tumor markers may not be helpful. In terms of outcome, the findings of metastatic tumor cells in the bone marrow indicate a poor prognosis in patients with advanced-stage cancer. Here, in our experience of 8 cases, six of the 8 patients died with short survival times. The two DCBM/CUPS cases still alive at this writing had poorly differentiated adenocarcinoma (Case 1) and undifferentiated carcinoma (Case 2). The probability of primary cancers of the gastrointestinal or pancreas/gall bladder carcinomas was higher in Case 1 than in Case 2. In both cases, no primary lesion(s) were identified by endoscopic/imaging studies. Regarding the unknown primary tumor site in the case of neuroendocrine carcinoma, the authors suggested that the primary site might have regressed spontaneously or been unexplored due to a lack of sensitive imaging studies.[7] Our CUPS cases were possibly to be caused similarly. Alternatively, the primary site(s) may emerge in future thorough investigations if they survive longer.

Managing a DCBM or DCBM/CUPS case is difficult, although CUPS patients are usually treated with nonselective empirical chemotherapy.[12] Because of their older age, both of our patients chose palliative care instead of chemotherapy. Chromosomal instability is a hallmark of poor prognosis in patients with CUPS. Thus, to introduce molecularly targeted drugs, molecular analysis is currently under investigation.[13,14] Single-cell RNA-sequencing methods may help identify the cell of origin.[15] Additionally, whole-genome sequencing using fresh-frozen tissue and matched blood samples from cancer patients was proposed to be the most complete genetic tumor test since gene fusion analysis showed a concordance of 91.3% between DNA-based whole-genome sequencing and an orthogonal RNA-based gene fusion assay.[16] Comprehensive genomic profiling (CGP) has been introduced as a guiding tool for precision-centered oncological treatments.[17,18] Currently, FoundationOne®Liquid CDx CGP,[19] which was approved in March 2021 in Japan, is available. This test was described to show a turnaround of 12 calendar days, from specimen receipt to the issue date of the report.[19] However, in the therapeutic decision-making of our cases, based on the DCBM clinical data, where the survival from the time of diagnosis was very short (a median of 2 months), as noted in this study, both of our DCBM/CUPS cases declined chemotherapy. They chose to transfer to the palliative medical facility without CGP analysis. We regret that we could not persuade our patients of the necessity of the CGP test by the FoundationOne® liquid CDx. With the use of CGP, we may decide "which therapy is appropriate for the patient" based on molecular evidence-based interventions, guiding the selection of chemotherapy or palliative care for those with advanced cancer, such as DCBM or DCBM/CUPS.

This report has limitations: (1) it is a small cohort based on the patients we studied, (2) it lacked novel genetic information because the patients did not undergo molecular diagnosis. However, in this short communication, we have provided important information on how to improve outcomes in patients with DCBM or DCBM/CUPS.

Conclusions

The use of comprehensive genomic profiling in advanced cancer is currently recommended. however, in cases of elderly patients with DCBM or DCBM/CUPS, we must accumulate data on improved outcomes based on molecular evidence-based interventions, otherwise, the patients may choose palliative therapy.

Acknowledgments

The authors thank all staff members who took care of the patients.

Funding

None.

Conflict of interest

The authors declare no conflicts of interest.

Author contributions

Drafted the manuscript (KM, MY, SI), treated patients (KM, MY), engaged in bone marrow studies (SI), performed pathological studies (SM). All authors have made a significant contribution to this study and have approved the final manuscript.

Ethical statement

The study protocol was performed following the Helsinki Declaration as revised in 2013. This report is a case series, approved by the institutional review board (Uji-Tokushukai Medical Center Ethics Committee; IRB approval No. 2023-42). Written informed consent was obtained from the patients, for the publication of the case series, and the accompanying images.

References

[1] Gajendra S, Sharma R. Cytomorphological evaluation of non-haematopoietic malignancies metastasizing to the bone marrow. Am J Blood Res 2023;13(1):1–11. PMID:36937461.
[2] Hayashi H, Haruyama H, Emura Y, Kaizuka I, Ozeki T, Kaizuka K. Disseminated carcinomatosis of the bone marrow study of a type of metastatic cancer and relationship of microangiopathic hemolytic anemia or disseminated intravascular coagulation. Jpn J Cancer Clin 1979;25(4):329.
[3] Lee MS, Sanoff HK. Cancer of unknown primary. BMJ 2020;371:m4050. doi:10.1136/bmj.m4050, PMID:33288500.
[4] Löffler H, Puthenparambil J, Hielscher T, Neben K, Krämer A. Patients with cancer of unknown primary: a retrospective analysis of 223 patients with adenocarcinoma or undifferentiated carcinoma. Dtsch Arztebl Int 2014;111(27-28):481–487. doi:10.3238/arztebl.2014.0481, PMID:25138727.
[5] Pavlidis N, Pentheroudakis G. Cancer of unknown primary site. Lancet 2012;379(9824):1428–1435. doi:10.1016/S0140-6736(11)61178-1, PMID:22414598.
[6] List C, Parmentier S, Jahn S, Schuler U, Kroschinsky F. [Bone marrow carcinosis as initial presentation of adenocarcinoma]. Internist (Berl) 2011;52(3):324–327. doi:10.1007/s00108-010-2657-7, PMID:20941476.
[7] Shi XB, Deng WX, Jin FX. Bone marrow metastatic neuroendocrine carcinoma with unknown primary site: A case report and review of the literature. World J Clin Cases 2022;10(30):11074–11081. doi:10.12998/wjcc.v10.i30.11074, PMID:36338238.
[8] Matsumoto K, Kikuchi K, Kikuyama T, Saito G, Adachi T, Watanabe A, *et al*. Disseminated Bone Marrow Carcinomatosis Due to Malignant Melanoma of Unknown Primary Origin. Intern Med 2021;60(21):3469–3472. doi:10.2169/internalmedicine.7274-21, PMID:34024857.
[9] Wang C, Rabah R, Blackstein M, Riddell RH. Bone marrow metastasis of angiosarcoma. Pathol Res Pract 2004;200(7-8):551–555. doi:10.1016/j.prp.2004.05.003, PMID:15462503.
[10] Imashuku S, Hashikura H, Nagasaka T. Natural history of epithelioid hemangioendothelioma that progressed over 20 years. Pediatr Blood Cancer 2020;67(6):e28261. doi:10.1002/pbc.28261, PMID:32307864.
[11] Hickman AD, Bezerra ED, Roden AC, Houdek MT, Barlow JD, Robinson SI, *et al*. An unusual case of aggressive malignant spread of epithelioid hemangioendothelioma. Rare Tumors 2021;13:20363613211010858. doi:10.1177/20363613211010858, PMID:33959241.
[12] Rassy E, Parent P, Lefort F, Boussios S, Baciarello G, Pavlidis N. New ris-

ing entities in cancer of unknown primary: Is there a real therapeutic benefit? Crit Rev Oncol Hematol 2020;147:102882. doi:10.1016/j.critrevonc.2020.102882, PMID:32106012.
[13] Yan N, Zhang Y, Guo X, Yuan D, Tian G, Yang J. A Review on Cancer of Unknown Primary Origin: The Role of Molecular Biomarkers in the Identification of Unknown Primary Origin. Methods Mol Biol 2020;2204:109–119. doi:10.1007/978-1-0716-0904-0_10, PMID:32710319.
[14] Olivier T, Fernandez E, Labidi-Galy I, Dietrich PY, Rodriguez-Bravo V, Baciarello G, *et al*. Redefining cancer of unknown primary: Is precision medicine really shifting the paradigm? Cancer Treat Rev 2021;97:102204. doi:10.1016/j.ctrv.2021.102204, PMID:33866225.
[15] Lazic D, Kromp F, Rifatbegovic F, Repiscak P, Kirr M, Mivalt F, *et al*. Landscape of Bone Marrow Metastasis in Human Neuroblastoma Unraveled by Transcriptomics and Deep Multiplex Imaging. Cancers (Basel) 2021;13(17):4311. doi:10.3390/cancers13174311, PMID:34503120.
[16] Roepman P, de Bruijn E, van Lieshout S, Schoenmaker L, Boelens MC, Dubbink HJ, *et al*. Clinical Validation of Whole Genome Sequencing for Cancer Diagnostics. J Mol Diagn 2021;23(7):816–833. doi:10.1016/j.jmoldx.2021.04.011, PMID:33964451.
[17] Pankiw M, Brezden-Masley C, Charames GS. Comprehensive genomic profiling for oncological advancements by precision medicine. Med Oncol 2023;41(1):1. doi:10.1007/s12032-023-02228-x, PMID:37993657.
[18] Hirakawa T, Doi M, Hamai K, Katsura R, Miyake S, Fujita S, *et al*. Comprehensive genomic profiling of Japanese patients with thoracic malignancies: A single-center retrospective study. Respir Investig 2023;61(6):746–754. doi:10.1016/j.resinv.2023.08.005, PMID:37714093.
[19] Milbury CA, Creeden J, Yip WK, Smith DL, Pattani V, Maxwell K, *et al*. Clinical and analytical validation of FoundationOne®CDx, a comprehensive genomic profiling assay for solid tumors. PLoS One 2022;17(3):e0264138. doi:10.1371/journal.pone.0264138, PMID:35294956.